

## Renovascular Arterial Hypertension Due to Triple Renal Arteries Stenoses: One Session Successful Stenting

Ileana Antohe<sup>1</sup>, Rotar M.<sup>2</sup>, Raluca Minea<sup>3</sup>

<sup>1</sup> M.D. Phd., University Of Medicine And Pharmacy "Gr. T. Popa", Iași, Romania

<sup>2</sup> M.D. Phd., Department Of Interventional Cardiology, "Elytis" Hospital, Iași, Romania

<sup>3</sup> Phd., Department Of Artistic Anatomy, University Of Arts "G. Enescu", Iași, Romania

---

**Abstract:** The paper presents a case of a 65 year old white male with atherosclerosis, severe left triple renal arteries stenoses and secondary renovascular hypertension (RVH). The patient was treated in a single session by percutaneous balloon angioplasty and stenting of the three left renal arteries with important atherosclerotic lesions. The uneventful evolution permitted patient's discharge next day after the intervention, with antihypertensive and antiplatelet therapy. The authors discuss successively the morphogenetic phenomena involved in multiple renal arteries apparition, the historical contribution of a Renaissance anatomist to the description of renal blood supply variants and recent trends in atherosclerotic RVH (interventional versus medical approach).

**Keywords:** renovascular hypertension, multiple renal arteries, percutaneous angioplasty

---

### I. Introduction

The atherosclerotic disease is a frequent condition in patients with arterial hypertension and the involvement of the renal arteries can lead to renovascular arterial hypertension [16, 18]. Ostial occlusion of renal arterial sources produces renal hypoperfusion and hyperactivation of the renin-angiotensin-aldosterone axis, causing hypertension [10]. The interventional treatment of patients diagnosed with renal arterial disease through selective angiography is endoluminal balloon dilatation and stenting. The progress of both tools and technics of angioplasty have led to generalization of percutaneous renal artery repermeabilization. Despite this fact, the extensive data on consistent lots of renal hypertensive patients are missing from the literature [2, 15]. The angioplasty literature reported few cases of concomitant endoluminal dilatation and stenting of multiple renal arteries [11, 16]. Our paper aims to present a case of patient with RVH due to atherosclerotic, severe stenosis of left multiple renal arteries, treated by one session balloon dilatation and stenting, to discuss from historical perspective the variation of renal arterial pattern and their involvement in the RVH.

### II. Case report

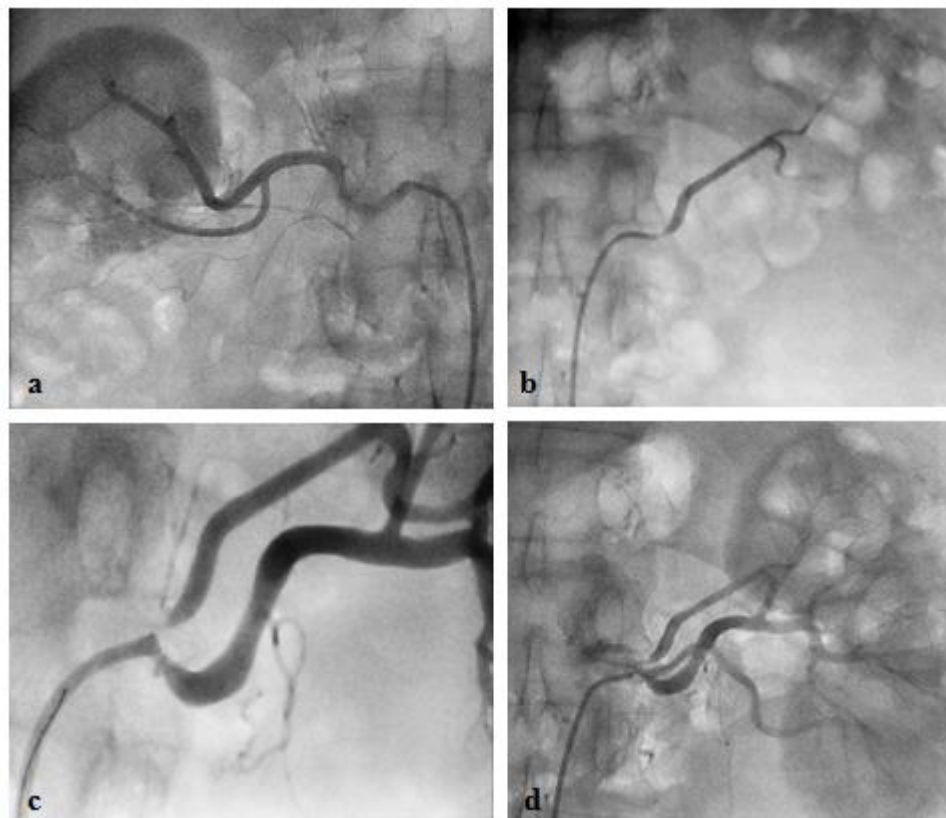
A 65 year old male, white, non-diabetic, obese patient (H 1.92 m, W 113 kg, BMI 30.65 kg/m<sup>2</sup>), with a serum creatinine of 0.89 mg/dl and a creatinine clearance of 132 ml/min was addressed to the interventional cardiologist for poor therapeutic control of his arterial hypertension (160/100 mm Hg), despite correct treatment with triple antihypertensive therapy (calcium channel blocker, diuretic and ACE inhibitor). We hypothesized that this patient had a secondary cause of hypertension, most probably RVH, due to an atherosclerotic renal artery stenosis. Angiographic evaluation of the aortic arch and coronary arteries provided normal findings and the renal angiogram detected multiple renal arteries, two on the right side and three on the left. The left arteries presented various degrees of severe stenoses: 95% stenosis of the left superior renal artery (fig 1b), 90% stenosis of the left middle renal artery (fig. 1c) and 95% stenosis of the inferior one (fig 1 d). On the right side the main renal artery was 80% patent (fig. 1a). The inferior third of the right kidney, supplied by a completely occluded supplementary thin, long, sinuous inferior polar artery, did not opacify. A fine arteriolar network seems to indicate the development of collateral circulation.

Percutaneous angioplasty and stenting of the three left renal arteries with important atherosclerotic lesions was performed in a single session after a bolus of 5.000 IU unfractionated Heparin was administered. A RDC 7F guiding catheter was placed in the abdominal aorta, facing the left renal arteries; wiring with coronary 0.014"BMW Intermediate II and sequential pre-dilatation with Maverick 3.0/20 mm balloon of the 3 arteries were performed. Superior polar and middle renal arteries were stented with simultaneous two kissing Everolimus DES Xience Pro 4.0/18 mm coronary stents inflated up to 20 atm. The inferior polar was stented afterwards using coronary Xience Pro 3.5/18 mm deployed with 18 atm.

The mild stenosis of the main renal artery remained untreated (fig. 1). The post-interventional evolution was uneventful and the patient was discharged one day after the procedure with the same

antihypertensive schedule and double antiplatelet therapy (Clopidogrel 75 mg/day for six months and Acetyl salicylic acid 75 mg/day, sine die).

Routine control patient's evaluation at three and six month showed that the serum creatine decreased from 0.89 mg/dl to 0.65 mg/dl and blood pressure improved (post-procedural from 160/100 mm Hg to 140/90 mm Hg and was optimally controlled afterwards).



### III. Discussion

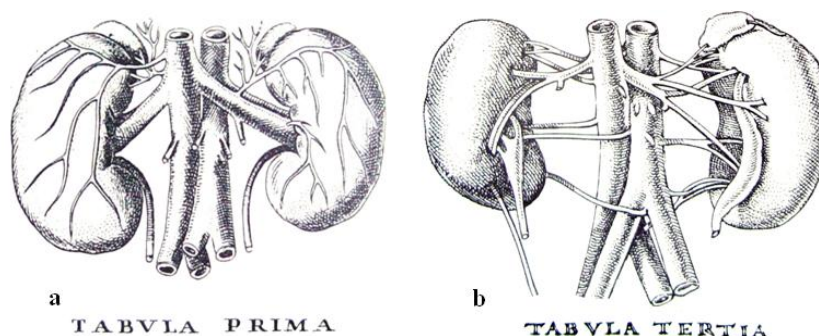
During the 6th-9th weeks of embryogenesis, the metanephric kidneys ascend from their initial paracloacal situation to their definitive location in the lumbar region. The ascending kidney becomes progressively vascularized by caudocranial serial arterial branches from the aorta. Normally, these transient primitive renal arteries regress in sequential manner and, when the ascent has been completed, each kidney is finally supplied by a single main renal artery. The persistence of one of these transient arteries results in an accessory renal artery [14].

Multiple renal arteries have been known from the beginnings of human body studies by dissection but the first scientific report [5] belongs to Bartholomeus Eustachius (1520-1574) who, in *Tabulae Anatomicae* [7], presented the normal kidney blood supply (fig 2 a) and various combinations (2-8 branches) of multiple renal arteries and veins (fig. 2 b). He also clearly and thoroughly described the adrenal glands (*Tabulae I-VII*), named by the author *glandula renis incumbens* (lat.: small gland lying above the kidney), with its correct blood supply and surprising details (e.g. the left middle suprarenal vein leaving the gland through its anterior face – *Tabula secunda*). After Eustachius, the anatomical literature enriched day by day and century by century, with new and spectacular descriptions of anatomical variants that proved their practical importance with the development of surgery and of imagistic exploring technics.

Cooper [6] underlines the importance of knowing the variants of the renal arteries, whose reported incidence increased during last years [4, 17], along with the increasing accuracy of the detection methods. So did the frequency of renal transplantation, vascular reconstruction for congenital or acquired defects and endovascular approach to arterial stenotic lesions [12].

RVH is present in approximately 1–3% of the general population [1]. In patients with concomitant atherosclerotic arterial disease, the prevalence of RHT increases to about 9.5% [9]. The prevalence of atherosclerotic renal arterial stenosis is reported to be increased in the old aged population from western countries, along with improved survival rates, due to the significant developments of the renal revascularization techniques [3]. However, the controversies and debates concerning the opportunity of these two therapeutic

approaches (medical versus endovascular interventional procedures) remain actual [6]. The value of the benefits obtained by invasive procedures has to be considered taking into account the possible risks (systemic or renal thromboembolic or hemorrhagic accidents) [13].



The anatomic risk factor for the patients with RHT consist in the presence of supernumerary renal arteries but the today prospective controlled data are insufficient and future randomized trials are needed [8]. However, in our case, percutaneous renal angioplasty and stenting significantly reduced the blood pressure.

#### IV. Conclusion

We have presented a case of a 65 years old patient with RVH and atherosclerotic stenosis of multiple renal arteries (two on the right and three on the left sides respectively), successfully treated by angioplasty and stent implantation. Our study demonstrated that treatment of multiple renal arteries stenosis is still an important technical challenge that needs a careful case planning. The knowledge of renal arteries variants is imperiously necessary and requests patient pre-procedural angiographic evaluation. In order to reduce progression to renal failure, once diagnosed renal artery stenosis requires immediate intervention.

**Conflict of interest** The authors declare no conflict of interest.

#### References

- [1]. Adriaenssens T, Kastrati A, Schömig A (2007) Successful stenting of bilateral multiple renal arteries in a patient with renovascular hypertension *J. Inv. Cardiol.* 19, 345-237.
- [2]. Balk E, Raman G, Chung M, et al. (2006) Effectiveness of management strategies for renal artery stenosis: a systematic review. *Ann Intern Med.* 145(12):901-12.
- [3]. Bax L et al. (2009) Stent placement in patients with atherosclerotic renal artery stenosis and impaired renal function. *Annals Int Med* 150:840-848.
- [4]. Bordei P, Antohe DS (2002) Anatomical study of triple renal arteries, *Morphologie*, 86, (274):37-41.
- [5]. Choulant L (1962) History and bibliography of anatomic illustration Hafner, New York, pp. 200-204.
- [6]. Cooper CJ, Murphy TP, Cutlip DE, Jamerson K, et al. (2014) Stenting and Medical Therapy for Atherosclerotic Renal-Artery Stenosis, *N Engl J Med*; 370:13-22 10753.
- [7]. Eustachius B *Tabulae Anatomicae*, commented by Joh. Maria Lancisi, Roma, MDCCXXII.
- [8]. Foy A, Ruggiero NJ, Filippone EJ (2012) Revascularization in renal artery stenosis. *Cardiol Rev.* Jul-Aug 20(4):189-93.
- [9]. Garovic VD, Textor SC (2005) Renovascular hypertension and ischemic nephropathy. *Circulation*, 112:1362-1374.
- [10]. Hirsch A et al. (2006) ACC/AHA Guidelines for the management of patients with peripheral arterial disease. *J Am Coll Cardiol* 47(6):1239-312.
- [11]. Mehan VK, Meier B (1995) Multiple renal artery stenting with half (disarticulated) Palmaz Schatz coronary stents and simultaneous coronary angioplasty. *Int Heart J.*
- [12]. Moreno-Alarcón C, Server-Pastor G, Lopez-Gonzales PA (2013) Must We Still Be Worried About Multiple Arteries in Kidney Transplantation? *Nephrol. Mon.*, 5(1): 692-696.
- [13]. Nordmann AJ, Woo K, Parkes R, et al. (2003) Balloon angioplasty or medical therapy for hypertensive patients with atherosclerotic renal artery stenosis? A meta-analysis of randomized controlled trials. *Am J Med* 226:821-826.
- [14]. O'Rahilly R, Fabiola Müller (1996) *Human Embryology & Teratology* Willey-Lyss, 273-280.
- [15]. Plouin PF, Bax L (2010) Diagnosis and treatment of renal artery stenosis. *Nat Rev Nephrol.* (2010); 6 (3):151-9.
- [16]. Sharma GL, Morice MC, Catineau P (2002) Successful angioplasty of tripolar renal arteries in a single setting: A case report. *J Invasive Cardiol* 14:457-460.
- [17]. Shane Toubbs R. Shoja MM, Loukas M (2016) *Bergmann's Comprehensive Encyclopedia of Human Anatomic Variation*, Willey 1315-1317.
- [18]. Zeller T, Frank U, Muller C et al. (2004) Stent-supported angioplasty of severe atherosclerotic renal artery stenosis preserves renal function and improves blood pressure control: Long-term results from a prospective registry of 456 lesions. *J Endovasc Ther* 11:95-106.